

# Review of Surgical Decompression of Three Cases of Ossified Ligamentum Flavum Causing Myelopathy

MUHAMMAD HANIF, RANA MUHAMMAD ARSHAD, MUHAMMAD TARIQ SOHAIL

## ABSTRACT

Ossifications of spinal ligaments, such as ossification of ligamenta flava (OLF) and ossification of posterior longitudinal ligament (OPLL) in the cervical spine, is common and usually asymptomatic. Once cervical myelopathy and radiculopathy occurs due to the OPLL, OLF or both, surgical managements are often required when conservative treatment is not effective. The diagnosis is based on computed tomographic (CT) scan or magnetic resonance (MRI) imaging. The postoperative prognosis depends on the severity and duration of the cervical myelopathy. High cervical ossified ligamentum flavum (OLF) is rare and may cause progressive quadriparesis and respiratory failure. In dealing with cervical OLF, carefully preserving facets during laminectomy or laminoplasty helps in maintaining normal cervical spinal curvature. In our two patients of OLF in cervical spine, evident on MRI and sagittal reconstruction CT showing lateral bars and ossified ligamentum flavum causing thecal compression and one case of dorsal spine with hypertrophied OLF at D<sub>9-11</sub> causing canal narrowing and thecal compression were treated by decompressive laminoplasty and laminectomy respectively resulting in appreciable relief in myelopathy in two patients. One of our patient with high cervical OLF and OPLL did not improved in immediate post-op period rather developed respiratory complications and aspiration pneumonia subsequently leading to mortality.

**Key words:** Myelopathy, decompression, ossified ligamentum flavum

---

## INTRODUCTION

Ossification of the flaval ligament (OLF), also known as ossification of the yellow ligament, has been recognized as a cause of myeloradiculopathy since it was first reported by Polgar in 1920 by lateral radiographs<sup>1</sup>. The coexistence of OLF and OPLL is relatively rare and typically contributes to severe radiculopathy as well as myelopathy. OPPL has been found at the thoracic spine in only 11%-25% of patients with cervical ossification, whereas OLF of the thoracic spine has frequently been associated with cervical OPLL. OLF is an acquired degenerative disease mainly affecting 20% of Asian individuals older than 65 years mostly affecting Japanese population rather rarely affecting our population in Pakistan<sup>2,3</sup>. Some authors have correlated it to systematic diseases such as diabetes mellitus, hypoparathyroidism, Skeletal fluorosis, diffuse skeletal hyperostosis (DISH) ankylosing spondylitis, hemachromatosis, hyperthyroidism, and deposition of calcium pyrophosphate crystals<sup>4,5,6,7,8</sup>. Others have correlated OLF to the elevated plasma concentration of fibronectin (a proactive protein in endochondral ossification), independently of the patients endocrinological profiles. On the other hand, some reports highlighted the importance of the mechanical

factors in OLF development<sup>9</sup>.

OPLL accompanies DISH up to 50% of the time. The DISH, is characterized by ossification along the ventral aspect of the cervical vertebrae, is found in 15 to 30% of adults older than 65 years of age<sup>10</sup>.

The relative incidence of ossified ligamentum flavum (OLF) in the thoracic, lumbar and cervical spine is approximately 38.5% and 26.5% and 0.9% respectively<sup>11,12</sup>.

## CASE REPORTS

We reviewed three cases of OLF and OPLL involving cervical and dorsal spine, all presented with signs of myloradiculopathy of varying degree. All were studied clinically and radiologically.

**Case 1:** Twenty eight years old female patient presented with six months history of asymmetrical spastic progressive quadriparesis with (power grade 4/5 of upper limbs and 3/5 in lower limbs). She had hyperreflexia, moderate to severe spasticity and loss of tactile, pain and posterior column sensations below C<sub>3</sub>. Hoffman sign and reverse radial reflex were positive. Cerebellar signs were negative. Her metabolic profile was normal except serum calcium 7.8 mg% and serum phosphate 2.1 mg%.

---

*Department of Orthopaedic and Spine Surgery, King Edward Medical University Mayo Hospital, Lahore*  
Correspondence to Dr. Muhammad Hanif, Assistant Professor Email: hanifspine@gmail.com

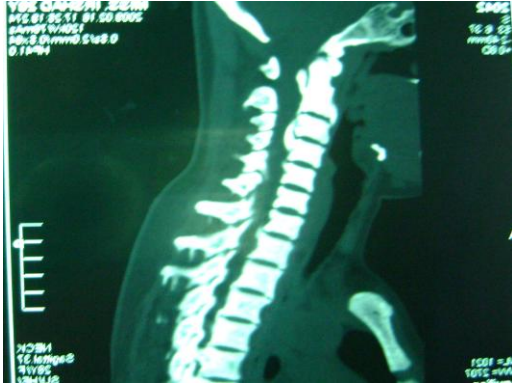

Fig. 1: CT film of the same patient showing focal ossifications of the PLL

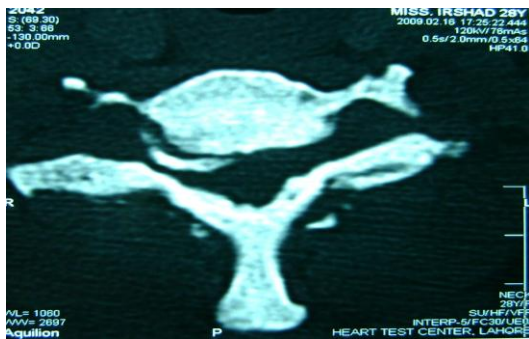


Fig 2 CT scan showing lateral bars of OPLL

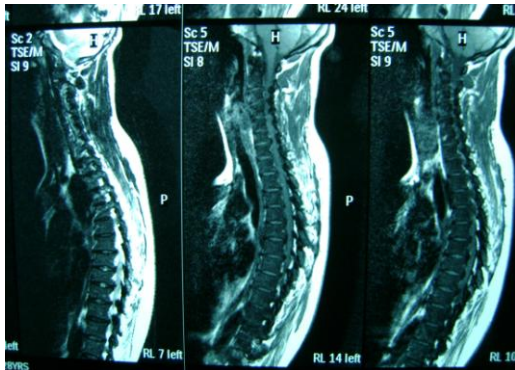


Fig: 3 MRI Picture showing cord compression at C:2 to 5 levels

CT with sagittal reconstruction showing ossified bars of PLL with narrowing of canal at C<sub>1-2</sub> and C<sub>3-4</sub> level [Fig 1, 2]. MRI: sagittal T<sub>2</sub> weighted images of cervical spine showing cervical canal stenosis at multiple levels C<sub>2-5</sub>. Hypertrophied ossified ligamentum flavum is seen as hypointensities on the dorsal aspect of spinal canal [Fig. 3].

A de-compressive posterior open door laminoplasty was performed. The spinal canal was tight with loss of epidural fat. The OLF was adherent to outer layer of dura which was carefully separated.

Excessive bulging of the spinal cord through the surgical corridor was noted. Excessive epidural bleeding was controlled with spongstones. There was no CSF leak per operatively. Patient did not improved neurologically in immediate post-op period rather developed respiratory complications and aspiration pneumonia subsequently leading to mortality three weeks after surgery.

**Case 2:** Forty Six years old male patient presented with progressive burning sensation in whole body below neck, followed by progressive spastic quadriplegia for six months with intact spinstar control. CNS examination revealed intact higher mental functions, cranial nerves and memory. Motor examination revealed hyperreflexia, severe spasticity and power 4/5. Sensations reduced below the clavicles. Lhermette and Hoffman signs were present and cerebellar signs were negative.

Metabolic profile and thyroid function tests were normal. Radiographic survey showing X-ray chest normal, X-rays of cervical and lumbar spine with osteophytes and syndesmophytes [Fig. 4,5].

C.T with sagittal reconstruction revealed multiple levels PLL ossification and canal narrowing in cervical spine [Fig. 6]. MRI could not be done due to femoral implants of previous surgery for bilateral femoral fractures.

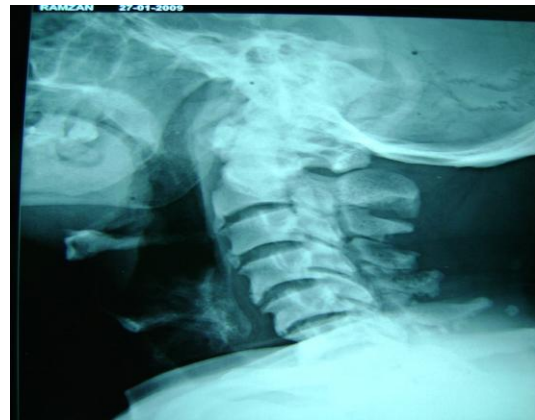

Fig. 4: X-ray cervical Spine lateral view

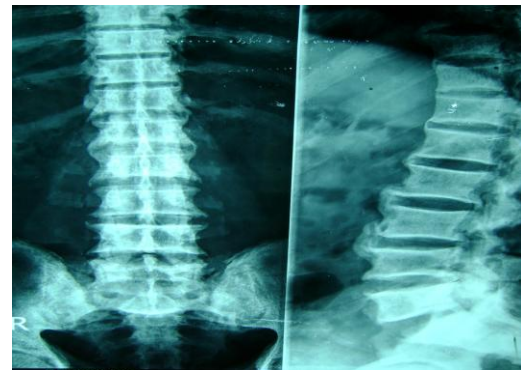


Fig: 5 Radio Graph showing osteophytes and Syndesmophytes

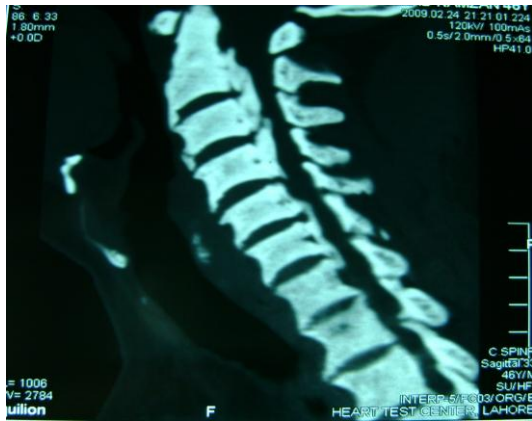

Fig: 6 CT with sagittal reconstruction showing multilevel OPLL and canal narrowing in cervical spine

A de-compressive open door laminoplasty was performed without any dural breach. The post operative course was uneventful without any complication. At 3 months follow up, he was able to walk without support.

**Case 3:** Fifty five years old female patient presented with five years old history of progressive weakness of both legs with power grade 0/5, severe spasticity and loss of pain and tactile sensations below D<sub>9</sub> with intact spinothalamic tract control. MRI showing hypertrophied OLF as multiple hypointensities on dorsal aspect of D<sub>9-11</sub>, with canal narrowing and spinal cord compression [Fig. 7]. Patient underwent posterior decompression laminectomy from D<sub>9-11</sub>. Post operative recovery was uneventful. At 3 months follow up the patient got improvement in her power (2/5) and sensations in the lower limb but developed bed sores and is under treatment.

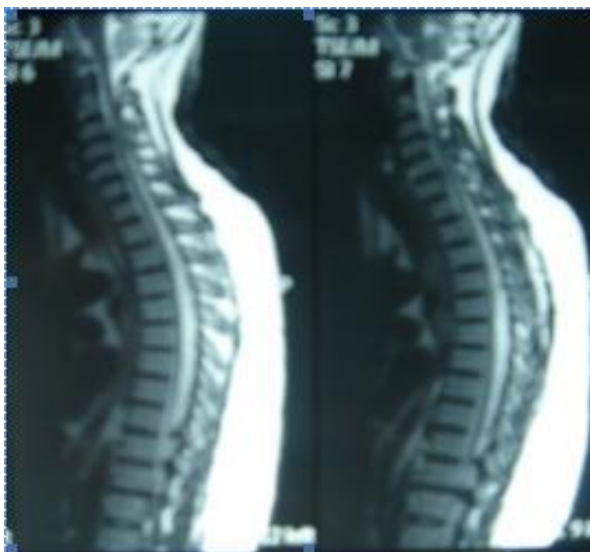

Fig: 7 MRI showing hypertrophied OLF as multiple hypointensities on dorsal aspect of D<sub>9-11</sub>.

## DISCUSSION

The underlying etiology and pathogenesis of OLF and OPLL remains an enigma<sup>4,5,6</sup>. However, the association of OLF and OPLL may share similar etiology and pathogenesis with other hyperostotic conditions e.g. ankylosing spondylitis, Forestier disease etc<sup>13</sup>.

OPLL is characterized by hyperplasia of cartilage cells with eventual endochondral ossification of posterior longitudinal ligament. It has been suggested that clinical manifestations related to thoracolumbar ossification are more severe than those associated with cervical involvement, although patients with the former may be entirely asymptomatic.

The most frequently reported location of OLF is the lower third of the thoracic spine. The second peculiarity was the presence of pseudodegenerative changes at the interface between the two separated bony outgrowths, leading to a pseudorathritic pattern of so called neo-joint or neoarticulation<sup>14,15</sup>.

OLF frequently occurs at the thoracic and thoracolumbar regions below C<sub>6-7</sub>, as ossification starts at the densely adherent ligament-osseous junction (enthesis); increased LF craniocaudal thickness combined with a narrower thoracic canal diameter leads to its earlier detection; and static tension causes decreased elastic fibers and the emergence of hyalinized collagen fibers, fibrocartilaginous cells and interligamentous calcification.

Cervical OLF is usually rare as cervical flexion-extension enables LF to frequently become lax and thus maintain its elastic fibers. A similar situation in the thoracolumbar region produces stress on the LF between the rigid rib cage above and the flexible lumbar spine leading to a higher frequency of OLF in this region<sup>11</sup>. Under this cyclical stress significant degradation of elastic fibers, fiber bundle degeneration, decrements in fiber diameter and fragmentation occur. The progress of calcification and ossification are closely associated with the degeneration of elastic fibers with expression of bone morphogenetic protein-2, transforming growth factor beta, and vascular endothelial growth factor in the ossification front.

The appearance of OLF on CT may be of three types, lateral, diffuse, thick and nodular. Our patients had predominantly diffuse type of OLF. A strong association with ossified posterior longitudinal ligament and with OLF at other sites of the spine has also been noted. An symptomatic cervical OLF associated with the symptomatic thoracic one has been reported emphasizing the role of screening MRI of the entire spine. The degree of spinal cord

compression by the OLF on intrathecal contract CT has been classified as: Type I: partial contrast media ring deficit; Type II: narrowing of characteristics of contrast media ring; and Type III: disappearance of contrast media ring<sup>12</sup>. A decompressive laminectomy including one level above and below the lesion, was the procedure of choice<sup>11</sup>. During drilling, cord injury was avoided by gently making the OLF wafer-thin, disconnecting it from the vertebral body in the lateral spinal gutters on the side of the dura using micro-Kerrison's punches; and then gently elevating it from the dura. In case the dura is densely adherent to the OLF and gets opened during its excision then a fat fascial graft may be placed with fibrin glue in the gutter created. In case the rent is large then a lumbar cerebrospinal fluid drain for three days with oral acetazolamide 250mg OD may be added. In certain cases, the OLF being adherent to the outer wall of the dura may had to be excised along with it. A pure formaminotomy and extended hemilaminectomy would have caused difficulty in defining the OLF-duramater interface and also in controlling epidural bleeding by the narrow surgical corridor. The chances of cord injury above and below the decompressed levels are high as the structures in the spinal canal are very tight indicated by the excessive bulging of spinal cord/dura through the surgical corridor. The high cervical combined OLF and OPLL with gross narrowing and myelopathy may result in failure of decompression which led to mortality in one of our cases.

Thus besides meticulous neurological examination, a thorough MRI of the whole spine is also strongly recommended. The presence of one level ossification should alert the surgeon of the possibility of multiple lesions (e.g., type II or III). It has been reported that electrophysiological diagnosis may be useful for establishing the responsible lesions in patients with multilevel spinal stenosis. In terms of the surgical treatment for tandem spinal ossifications, how to establish the surgical extent is very important. Failure to do so may result in the wrong operative approach, inadequate decompression and increased neurological dysfunction.

## REFERENCES

1. Polgar F. *Über interakuelle wirbelverkalkung*. Fortschr Geb Rongenstr Nukleomed Ergazungsband 1920; 40:292-8.
2. Arafat QW, Jackowski A, Charada SV, West RJ: Case report: Ossification of thoracic ligamentum flavum in a caucasian: A rare cause of myelopathy. *br J Radiol* 1993; 66(792): 1193-6.
3. Casino CM, Blando AV: Calcification of ligamentum flavum causing spinal cord compression in a stroke patient. *Arch Phys Med Rehab* 1994; 75: 226-8.
4. Gupta RK, Agarwal P, Kumar S, Surana PK, Lal JH, Misra UK: Compressive myelopathy in flurosis. *MRI. Neuroradiology* 1996; 38: 338-42.
5. Mitra SR, Gurjan SR, Mitra KR: Degenerative disease of the thoracic spine in central India, *Spinal Cord* 1996; 34:333-7.
6. Omojola MF, Cardoso ER, Fox AJ, Drake CG, Durward QJ: Thoracic myelopathy secondary to ossified ligamentum flavum: case report. *J Neurosurg* 1982; 56: 448-50.
7. Shiraishi T, Crock HV, Lewis P: Thoracic myelopathy due to isolated ossification of the ligamntum flavum. *J Bone Joint Surg* 1995; 77-B:131-3.
8. Yonenobu K, Ebara S & Fujiwara K et al. Thoracic myelopathy secondary to ossification of the spinal ligment. *J Neurosurg* 1987; 66:511-6.
9. Maigne JY, Ayral X, Guerin-Surville H. Frequency and size of ossification in the caudal attachments of the ligamentum flavum of the thoracic spine. Role of rotary strain in their development. *An anatomic study of 121 spines. Surg Radiol Anat* 1992; 14:119-24.
10. Nancy Epstein. Ossification of the cervical posterior longitudinal ligaments: a review. *Neurosurg Focus* 2002; 13(8):1-8.
11. Kobayashi S, Okada K, Onoda K, Horikoshi S. Ossification of the cervical ligamentum flavum. *Surg Neurol* 1991; 35:234-8.
12. Fujiwara M, Bitoh S, Hasegawa H, Nakata M, Hata H. A case of nodular calcificaqtion of the ligamentum flavum with ossification of the posterior longitudinal ligament in the cervical spine. *No shinkei Geka* 1982; 10:769-74.
13. Kudo S, Ono M, Russell WJ. Ossification of the thoracic ligamenta flava. *Am J Roentgenol* 1983; 141: 117-21.
14. Sugimura H, kakitsubata Y, Suzuki Y, Kakitsubata S, Tamura S, Uwada O, et at, MRI of ossification of ligamentum flavum. *J Comput Assist Tomogr* 1992; 16:73-6.
15. Miyasaka K, Kaneda K, Sato S, Iwasaki Y, Abe S , Takei H, et at. Myelopathy due to ossification or calcification of the ligamentum flavum: radiologic and histologic evaluations. *AJNR Am J Neuroradiol* 1983; 4: 629-32.